

CORRESPONDENCE

Tracheal introducers and airway trauma COVID-19. [Br J Anaesth] (2020) [Epub ahead of print]

Massimiliano Sorbello^{1,*}, Iljaz Hodzovic², Giacomo Cusumano¹ and Giulio Frova³

¹Catania, Italy, ²Cardiff, UK and ³Brescia, Italy

*Corresponding author. E-mail: maxsorbello@gmail.com

Keywords: airway management; bougie; COVID-19; introducer; laryngoscopy; pneumothorax; tracheal intubation; tracheal trauma

Editor—We read with interest the paper by Abou-Arab and colleagues,¹ and we would like to make a number of comments related to airway management in coronavirus disease 2019 (COVID-19) patients. Our experience suggests that any COVID-19 patient should be considered *a priori* as having a difficult airway given the severity of hypoxaemia, difficulties arising from wearing personal protective equipment, and the challenging work environment. Obese patients might be at higher risk of difficult airway management,² and obesity seems to be both a risk factor for developing COVID-19³ and for poorer outcome.⁴ In most COVID-19 patients, tracheal intubation can be performed semi-electively, allowing time for patient assessment, team preparation, and discussion of airway management strategy.³ This includes patient positioning² and primary use of videolaryngoscopy given its efficacy and lower risk of contamination.³ We believe that maximising first-pass success is of paramount importance in COVID-19 patients to reduce the risk of respiratory and haemodynamic complications and airway team contamination. It is unclear from their description to what extent Abou-Arab and colleagues¹ were anticipating difficulty in managing the airway and what preparatory steps were taken.

It appears that noninvasive ventilation was not attempted before tracheal intubation. In addition to aiding the decision about the timing of intubation,³ this mode of respiratory support could have been used for preoxygenation, which is especially effective in hypoxaemic obese patients.^{2,3} Of the two patients presented, one received high-flow nasal oxygen,

the role of which is debated in COVID-19 patients,³ and the other was on 9 L min⁻¹ face-mask oxygen. Optimising oxygen delivery before intubation is likely to allow more controlled airway management and minimise the likelihood of an adverse airway event.

The authors¹ reported use of an intubating bougie in conjunction with direct laryngoscopy on both patients with Grade IV Cormack–Lehane laryngeal views. The likelihood of successful tracheal bougie placement with a Grade IV laryngeal view is quite low, whereas the risk of airway trauma as a result of blind bougie insertion is significant, so that use of a bougie in such a scenario is considered contraindicated.⁵ The two reported cases substantiate this concept. Other factors could have contributed to the reported airway trauma. Manikin studies suggest that single-use bougies, depending on construction material, are variably more rigid and likely to cause airway trauma when compared with the Eschmann multiple-use introducer (Smiths Medical, Minneapolis, MS, USA).⁶ This may be exacerbated by the inflamed airway mucosa in COVID-19 patients, which is likely to be frail and more prone to injury. The Chinese experience quotes a 5.9% incidence of pneumothorax during intubation in COVID-19 patients, but no association with bougie use is reported.⁷ The authors did not state if signs for confirming tracheal bougie placement, such as hold-up or tracheal clicks, were used. It was not clear from the report if only the bougie was inserted and withdrawn in the absence of position confirmation, or if the tracheal tube was removed after being railroaded over the bougie in the absence of tracheal placement confirmation. Such a clarification would facilitate understanding of the airway trauma mechanisms in the two reported cases, which

DOI of original article: [10.1016/j.bja.2020.04.004](https://doi.org/10.1016/j.bja.2020.04.004).

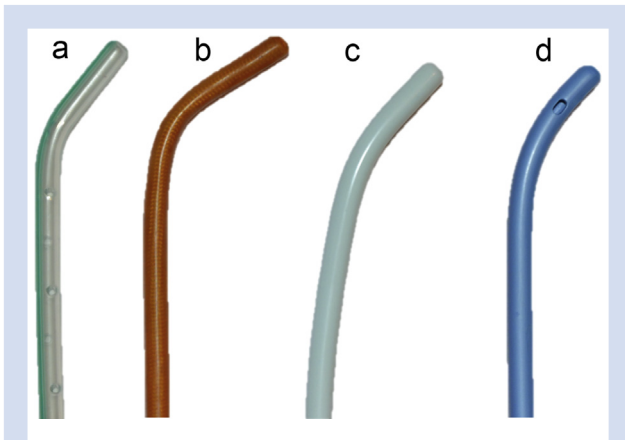


Fig 1. Tracheal introducers available on the market for adult patients. Note different tip curvatures/angles and construction materials: (a) Boussignac (Pebax; Vygon), (b) Venn multi-use introducer or reusable bougie (polyester tissue/resin; Eschmann; Smiths Medical), (c) single-use bougie/introducer (polyvinyl chloride; Smiths Medical), and (d) Frova intubation introducer (polyethylene intermediate density; Cook Medical, Bloomington, IN, USA).

could be associated with the tube as well rather than with the bougie alone.

Should such airway trauma occur, multidisciplinary evaluation is recommended. A conservative approach would be preferable especially in critical COVID-19 patients when indicated (minor tracheal tears above the level of the tracheal tube cuff).⁸ A bougie-induced lesion of the cricothyroid membrane and how that resulted in pneumothorax and pneumomediastinum in the second patient are also difficult to understand. Blind bougie advance against a resistance could explain it. We would advise even more caution than usual when using bougies in COVID-19 patients. It is critically important not to force the bougie advance, either when facing limited laryngeal views or when the bougie has passed the vocal cords. Any bougie advance past the carina carries a high risk of airway trauma⁵; hence, it should not be inserted more than 8 cm past the vocal cords.^{5,9} These precautions might be even more relevant in COVID-19 patients, whose inflamed airways may be more prone to trauma.

The Eschmann angled-tip bougie is exclusively produced by Smiths Medical (Minneapolis, MN, USA; <https://www.smiths-medical.com/products/airway-management/intubation-accessories/intubation-guides-and-stylets/tracheal-tube-introducers-and-guides>), and it is a reusable device, whereas Vygon (Écouen, France) produces a single-use stiffer 70 cm (15 Fr)⁻¹, angled-tip, Pebax[®] hollow introducer (<https://www.vygon.it/catalogo/prodotto/guida-per-sonde-endotracheali-bougie-di-boussignac-1/>) (Fig. 1). The statement that, 'the use of a bougie probably induced tracheal trauma worsening respiratory conditions and leading to urgent ECMO' does not sound correct. Lack of preparation, use of a direct laryngoscope as a primary intubation device, and

inappropriate bougie use likely all contributed to such an outcome. This simple device remains a precious adjunct for airway management when carefully used in conjunction with direct or videolaryngoscopy.¹⁰

Declarations of interest

MS has received paid consultancy from Teleflex Medical, Verathon Medical, and DEAS Italia; is a patent co-owner (no royalties) of DEAS Italia; and has received lecture grants and travel reimbursements from MSD Italia and MSD USA. GF has received royalties from Cook Medical (Frova Introducer; Bloomington, IN, USA) and Teleflex Medical (PercuTwist and EasyCric) for his airway device inventions. IH and GC declare no competing interests.

References

1. Abou-Arab O, Huette P, Berna P, Mahjoub Y. Tracheal trauma after difficult airway management in morbidly obese patients with COVID-19. *Br J Anaesth* 2020. <https://doi.org/10.1016/j.bja.2020.04.004>. Advance Access published on April 11, 2020
2. Petrini F, Di Giacinto I, Cataldo R, et al. Perioperative and periprocedural airway management and respiratory safety for the obese patient: 2016 SIAARTI Consensus. *Minerva Anestesiologica* 2016; **82**: 1314–35
3. Sorbello M, El-Boghdady K, Di Giacinto I, et al. The Italian coronavirus disease 2019 outbreak: recommendations from clinical practice. *Anaesthesia* 2020; **75**: 724–32
4. Memtsoudis SG, Ivascu NS, Pryor KO, Goldstein PA. Obesity as a risk factor for poor outcome in COVID-19 induced lung injury: the potential role of undiagnosed obstructive sleep apnoea. *Br J Anaesth* May 1, 2020. <https://doi.org/10.1016/j.bja.2020.04.078>. Advance Access published on
5. Sorbello M, Frova G. Frova introducer: neither a stylet nor simply an introducer. *Anaesthesia* 2008; **63**: 1010–1
6. Hodzovic I, Latto IP, Wilkes AR, Hall JE, Mapleson WW. Evaluation of Frova, single-use intubation introducer, in a manikin. Comparison with Eschmann multiple-use introducer and Portex single-use introducer. *Anaesthesia* 2004; **59**: 811–6
7. Yao W, Wang T, Jiang B, et al. Emergency tracheal intubation in 202 patients with COVID-19 in Wuhan, China: lessons learnt and international expert recommendations. *Br J Anaesth* April 10, 2020. <https://doi.org/10.1016/j.bja.2020.03.026>. Advance Access published on
8. Frova G, Sorbello M. Iatrogenic tracheobronchial ruptures: the debate continues. *Minerva Anestesiologica* 2011; **77**: 1130–3
9. Paul A, Gibson AA, Robinson OD, Koch J. The traffic light bougie: a study of a novel safety modification. *Anaesthesia* 2014; **69**: 214–8
10. Driver BE, Prekker ME, Klein LR, et al. Effect of use of a bougie vs endotracheal tube and stylet on first-attempt intubation success among patients with difficult airways undergoing emergency intubation: a randomized clinical trial. *JAMA* 2018; **319**: 2179–89