

# Ultrasound Is Superior to Palpation in Identifying the Cricothyroid Membrane in Subjects with Poorly Defined Neck Landmarks

## *A Randomized Clinical Trial*

Naveed Siddiqui, M.D., M.Sc., Eugene Yu, M.D., R.C.P.S.C., A.B.R., Sherif Boulis, M.D., F.R.C.P.C., Kong Eric You-Ten, Ph.D., M.D., F.R.C.P.C.

### ABSTRACT

**Background:** Success of a cricothyrotomy is dependent on accurate identification of the cricothyroid membrane. The objective of this study was to compare the accuracy of ultrasonography *versus* external palpation in localizing the cricothyroid membrane.

**Methods:** In total, 223 subjects with abnormal neck anatomy who were scheduled for neck computed-tomography scan at University Health Network hospitals in Toronto, Canada, were randomized into two groups: external palpation and ultrasound. The localization points of the cricothyroid membrane determined by ultrasonography or external palpation were compared to the reference midpoint (computed-tomography point) of the cricothyroid membrane by a radiologist who was blinded to group allocation. Primary outcome was the accuracy in identification of the cricothyroid membrane, which was measured by digital ruler in millimeters from the computed-tomography point to the ultrasound point or external-palpation point. Success was defined as the proportion of accurate attempts within a 5-mm distance from the computed-tomography point to the ultrasound point or external-palpation point.

**Results:** The percentage of accurate attempts was 10-fold greater in the ultrasound than external-palpation group (81% *vs.* 8%; 95% CI, 63.6 to 81.3%;  $P < 0.0001$ ). The mean (SD) distance measured from the external-palpation to computed-tomography point was five-fold greater than the ultrasound to the computed-tomography point ( $16.6 \pm 7.5$  *vs.*  $3.4 \pm 3.3$  mm; 95% CI, 11.67 to 14.70;  $P < 0.0001$ ). Analysis demonstrated that the risk ratio of inaccurate localization of the cricothyroid membrane was 9.14-fold greater with the external palpation than with the ultrasound ( $P < 0.0001$ ). There were no adverse events observed.

**Conclusions:** In subjects with poorly defined neck landmarks, ultrasonography is more accurate than external palpation in localizing the cricothyroid membrane. (ANESTHESIOLOGY 2018; 129:1132-9)

AIRWAY management is an important skill required for acute care physicians, including intensivists, anesthesiologists, and emergency medicine physicians. Difficult airways remain a major challenge that can lead to serious adverse outcomes and death.<sup>1,2</sup> In rare life-threatening airway crises of “cannot intubate, cannot oxygenate,” an emergency cricothyrotomy with the insertion of a breathing tube *via* the cricothyroid membrane is the only option.<sup>3,4</sup> When performing this potentially life-saving procedure, the first critical step is to palpate and correctly identify the cricothyroid membrane because its misidentification is a major cause of tube misplacements, leading to cricothyrotomy failures and serious complications.<sup>2</sup> However, accurate localization of the cricothyroid membrane using the conventional approach of external palpation is more challenging than anticipated where anesthesiologists, emergency medicine physicians, and trauma surgeons poorly localized the cricothyroid membrane.<sup>4-7</sup>

### Editor's Perspective

#### What We Already Know about This Topic

- Accurate identification of the cricothyroid membrane is key for success of emergency cricothyrotomy
- Ultrasound has been reported to identify the cricothyroid membrane more accurately than external palpation in patients with normal neck anatomy

#### What This Article Tells Us That Is New

- In this randomized clinical trial, 223 adult patients with neck pathologies such as previous neck surgery, irradiation, and/or neck mass who were scheduled for a neck computed-tomography scan were randomly allocated to either the ultrasound group or the external-palpation group
- Accuracy in identification of the cricothyroid membrane, defined as the distance from a point determined by the computed tomography within 5 mm, was 10-fold greater in the ultrasound group (81%,  $n = 114$ ) than the external-palpation group (8%,  $n = 109$ )

This article is featured in “This Month in Anesthesiology,” page 1A. This article has an audio podcast. This article has a visual abstract available in the online version. This work was presented at the 20th Annual Society of Airway Management Meeting in Newport Beach, California, September 14 to 17, 2017.

Submitted for publication December 27, 2017. Accepted for publication August 30, 2018. From the Department of Anesthesia and Acute Pain Service (N.S.), the Neuroimaging Faculty, Princess Margaret Hospital (E.Y.), the Departments of Anesthesia (S.B., K.E.Y.-T.) and Pain Management (K.E.Y.-T.), Mount Sinai Hospital, University of Toronto, Canada.

Copyright © 2018, the American Society of Anesthesiologists, Inc. Wolters Kluwer Health, Inc. All Rights Reserved. Anesthesiology 2018; 129:1132-9

Ultrasonography has become increasingly important in the practice of anesthesia, emergency medicine, and critical care.<sup>2</sup> In particular, ultrasonography has been proven to increase success, decrease complications, and enhance patient safety when performing invasive procedures.<sup>2</sup> Increasing evidence has shown a role for ultrasonography of neck landmarks in airway management to accurately identify the cricothyroid membrane.<sup>3–6,8</sup> Conversely, the traditional method of external palpation poorly identified the cricothyroid membrane.<sup>2</sup> Although the majority of the studies comparing ultrasound and external palpation of the cricothyroid membrane were performed on patients with normal neck landmarks, little is known of their performance on patients with poorly defined neck anatomy, particularly in patients with previous neck surgery, neck mass, and/or neck irradiation.

We hypothesized that ultrasound is more accurate than external palpation in identifying the cricothyroid membrane when compared to the accepted standard, computed-tomography scan. The objective of this randomized clinical trial was to compare the accuracy of ultrasound *versus* external palpation in localizing the cricothyroid membrane in patients with poorly defined neck landmarks.

## Materials and Methods

This prospective, single-center, single-blinded, randomized clinical trial was reviewed and approved by University Health Network Research Ethics Board (Toronto, Canada; approval No. 12-5327-BE). Written informed consent was obtained from all participants. Our trial is accessible on [clinicaltrials.gov](https://clinicaltrials.gov) with the identifier NCT01725828. The modifications that were made to the protocol are reflected on [clinicaltrials.gov](https://clinicaltrials.gov).

The study was conducted on 223 American Society of Anesthesiologists physical status I to III patients at least 18 yr of age with neck pathology who were scheduled for a neck computed-tomography scan at University Health Network hospitals (Toronto, Canada) from October 2012 to July 2014. All patients recruited in the study had neck pathologies including previous neck surgery, irradiation, and/or neck mass. We excluded patients who were unable to lie flat, those who were unable to maintain a neutral neck position, and those who refused to participate in the study. The patients' characteristics were recorded, including age, sex, neck circumference, ability to extend the neck, history of previous surgery on the neck, thyromental distance, sternomental distance, and history of difficulty in airway management. Patients were approached by the admitting nurse in the waiting area of the computed-tomography scan suite at the University Health Network and asked about their willingness to participate in a research study. If the patient was willing to participate, detailed information about the study was provided by the research assistant, and informed written consent was obtained. Then the patients

were assessed for eligibility to participate in the study, and eligible patients were assigned to the study groups by the research assistant. The neck anatomy of each patient was assessed by an independent anesthesiologist for the degree of difficulty in identifying the landmarks according to an established grading system<sup>2,6</sup>: easy, visual landmarks; moderate, requires light palpation of landmarks; difficult, requires deep palpation of landmarks; and impossible, landmarks not palpable. Subjects with a score of moderate, difficult, and impossible landmarks were recruited for the study. All patients were randomized by the statistician using a computer-generated random number table for group allocation: external palpation and ultrasound. Randomization assignments were placed in sequentially numbered concealed envelopes. After performing the screening, the envelope was opened by the research assistant, and the patient was assigned to either the ultrasound group or the external-palpation group.

### Assessment of the Cricothyroid Membrane

Assessment of the cricothyroid membrane using external palpation or ultrasound was performed by two anesthesia fellows (S.B. and Devdatta Desi, M.D., Research Associate, Department of Anesthesia and Pain Management, Mount Sinai Hospital, University of Toronto, Toronto, Canada) depending on their schedule availability.

**External Palpation of the Cricothyroid Membrane.** On the day of the computed-tomography scan, an anesthesia fellow (S.B. or D.D.) palpated the neck landmarks of patients in the external-palpation group and marked the anticipated entry point (external-palpation point) of a cricothyrotomy device using a radiopaque computed tomography-compatible sticker marker (ultrasound; SureMark Company, USA). The patients were supine with the neck in the same neutral position as in the computed-tomography scan. Identification of the cricothyroid membrane was performed using the index and third finger of the nondominant hand to palpate the thyroid cartilage in the midline starting from the cephalad and moving caudally to the cricothyroid cartilage.<sup>2</sup> The space between the inferior border of the thyroid cartilage and superior border of the cricoid cartilage is the cricothyroid membrane.

**Ultrasonography of the Cricothyroid Membrane.** The anesthesia fellows who were involved in the study received a 10-min didactic lecture followed by a 3-min video on the ultrasonographic and palpation techniques to identify the anatomical landmarks and the cricothyroid membrane. They were then given hands-on training at least five times with ultrasound.<sup>2</sup> Furthermore, both fellows had performed a minimum of 20 successful identifications of the cricothyroid membrane using external palpation and ultrasound, which is the required number to achieve competence in ultrasound identification of the cricothyroid membrane.<sup>9</sup> On the day of the computed-tomography scan, one of the anesthesia fellows who was available identified the cricothyroid membrane

of patients in the ultrasound group. The midpoint of the cricothyroid membrane (ultrasound point) was then marked with a SureMark sticker. Ultrasonography of the neck was performed as previously reported using the transverse and longitudinal approach as described by Kristensen<sup>3</sup> and Kristensen *et al.*<sup>10</sup> A portable ultrasound system with a 10- to 5-MHz linear-array transducer (Zonare Medical Systems, Inc., USA) was used for the ultrasound scans. Patients being scanned were positioned supine with the neck in the same neutral position as in the computed-tomography scan.

### Computed-tomography Image of the Neck

The neck computed-tomography image of each patient was read by a radiologist staff member who was the only one blinded to the group allocation. The cricothyroid membrane was identified between the inferior border of the thyroid cartilage and superior border of the cricoid cartilage. The digital ruler of the computed-tomography scan was used to measure the horizontal (x-axis) and vertical (y-axis) distance (millimeters) of the cricothyroid membrane. The intersection of the horizontal and vertical axes is referred as the midpoint of the cricothyroid membrane (computed-tomography point).

Our primary outcome was the accuracy in identification of the cricothyroid membrane, which was measured by a digital ruler in millimeters from the computed-tomography point to the ultrasound point or external-palpation point. We defined success as the proportion of accurate attempts within a 5-mm distance from the computed-tomography point to the ultrasound point or external-palpation point.

The study was initially planned with the primary outcome as the absolute distance (millimeters) between the computed-tomography point to the external-palpation point and ultrasound point. Since 2015, there has been an increasing number of studies on ultrasound identification of the cricothyroid membrane, which defined accuracy as a distance of 5 mm or less.<sup>2,4,7,11</sup> Thus, we included the proportion of accurate attempts as a distance of 5 mm or less as a secondary outcome in the clinical trial registration in June 2018. Keeping the same objective and focusing on more clinical relevance, we reported the primary outcome as the proportion of accurate attempts within a 5-mm distance from the computed-tomography point to the ultrasound point or external-palpation point.

The distance of 5 mm or less is based on several studies measuring the dimensions of the cricothyroid membrane.<sup>12,13</sup> This is clinically relevant because a puncture outside this limit is likely to be outside the cricothyroid membrane vertical dimension and may result in cricothyrotomy failure and/or cause unnecessary tissue injuries.<sup>12</sup>

Our pilot data indicated a 50% success rate for accurate identification of the cricothyroid membrane by external palpation. Based on current literature and the data obtained from our previous studies, we hypothesized a 70% success rate for accurate identification of the cricothyroid membrane when using ultrasound. To demonstrate a 20% improvement

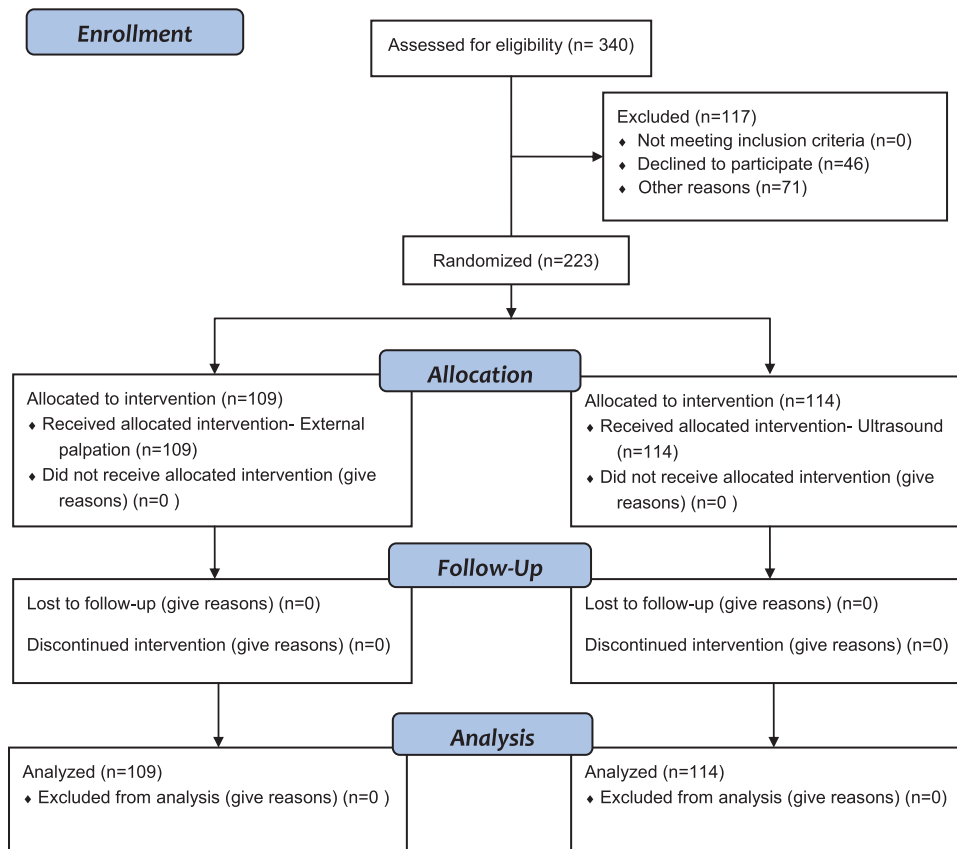
in the success rate at 80% power and a 5% significance level, a minimum number of 82 subjects was required in each of the experimental groups (external-palpation group and ultrasound group). To ensure sufficient power for the study, 109 patients were recruited to the external-palpation group, and 114 patients were recruited to the ultrasound group.

### Statistical Analysis

The characteristics of each group were presented with frequencies and percentages for categorical variables and compared using the chi-square test. For continuous variables, means and SDs were presented and compared using independent two-sample *t* tests. Normal distribution was checked by examining the histograms. The statistical model was changed from a logistic regression model to a Poisson regression model to examine the rate of successful identification of the cricothyroid membrane and to calculate risk ratios. Possible confounders including body mass index, neck circumference, thyromental distance, sternomental distance ability to extend the neck, previous surgery on the neck, history of difficult intubation, and difficulty of manual identification were adjusted for the model. The distance from the target location was compared between the groups using a *t* test. SAS version 9.3 (SAS Institute, USA) was used for the statistical analysis. All *P* values were two-sided, and a value of *P* < 0.05 was considered statistically significant.

### Results

In total, 340 subjects scheduled for a neck computed-tomography scan at University Health Network hospitals were assessed for eligibility. Of those 340, 117 subjects were excluded from the study. None of the participants were excluded from the study after randomization. However, patients who were unable to lie flat, those who were unable to maintain a neutral neck position, and those who refused to participate in the study were excluded at the time of recruitment. A total of 223 patients with poorly defined neck landmarks completed the study, with 109 and 114 patients randomized to the external-palpation and ultrasound groups, respectively (fig. 1). More than half of the patients in each group had previous neck surgery (table 1). The patients' characteristics were similar between groups except for a statistically significant difference in body mass index (table 1). Before the localization of the cricothyroid membrane, the degree of difficulty in palpating the neck landmarks was evaluated for each patient. Table 1 showed that the distribution of patients with various degrees of difficulty was similar between the groups. The localization points of the cricothyroid membrane determined by ultrasonography (ultrasound point) and external palpation (external-palpation point) were compared to the reference midpoint (computed-tomography point) of the cricothyroid membrane identified by computed-tomography scan. Figure 2 shows that the majority of the localization points identified by ultrasound were within 5 mm of the reference computed-tomography



**Fig. 1.** Consolidated Standards of Reporting Trials (CONSORT) flow diagram showing participant flow through each stage of the randomized controlled trial (enrollment, intervention allocation, follow-up, and data analysis).

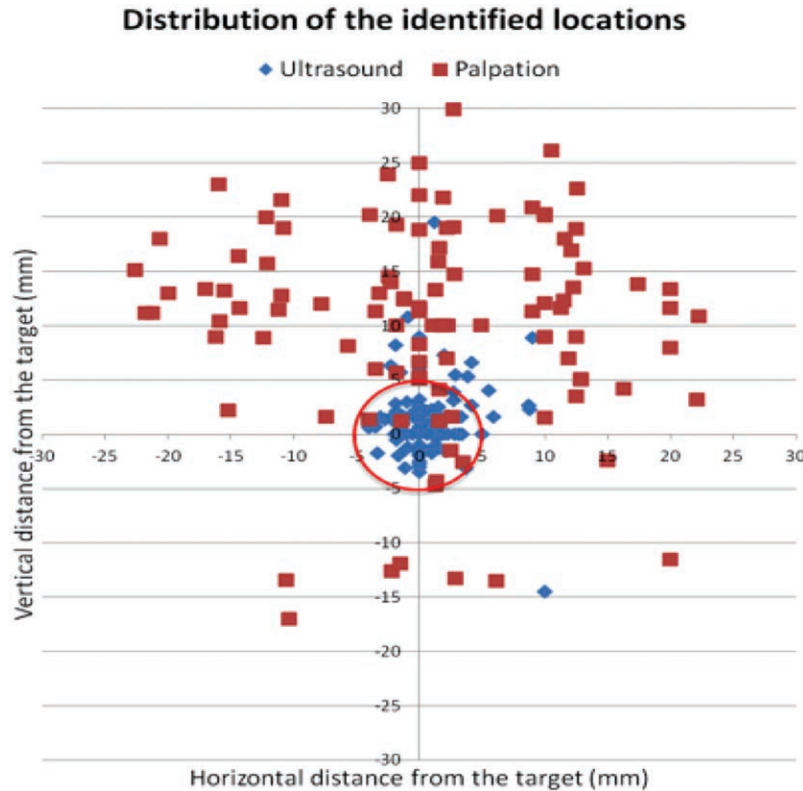
**Table 1.** Characteristics Comparison between the Two Groups

Variable	External Palpation (N = 109)	Ultrasound (N = 114)	P value
Male, No. (%)	71 (65%)	72 (63%)	0.758
Age, mean ± SD	57.4 (14.9)	57.0 (13.7)	0.800
Weight, mean ± SD, kg	75.2 (16.7)	72.2 (17.2)	0.185
Height, mean ± SD, cm	170 (12)	171 (9)	0.296
Body mass index, mean ± SD	26.1 (4.7)	24.6 (5.2)	0.020
Neck circumference, mean ± SD, cm	38.5 (3.9)	37.6 (5.0)	0.129
Thyromental distance, mean ± SD, cm	8.0 (1.1)	8.0 (1.4)	0.934
Sternomental distance, mean ± SD, cm	14.9 (2.0)	15.0 (1.8)	0.683
Ability to extend neck, No. (%)	101 (93)	100 (88)	0.216
Previous surgery on neck, No. (%)	60 (55)	59 (52)	0.622
History of difficult intubation, No. (%)	7 (6)	5 (4)	0.501
Difficulty of manual cricothyroid membrane identification, No. (%)			0.088
Impossible	15 (14)	6 (5)	
Difficult	29 (17)	36 (32)	
Moderate	65 (60)	72 (63)	

point, contrasting with a more scattered distribution of the localization points identified by external palpation. Our primary outcome was the accuracy in identification of the cricothyroid membrane, which was measured by a digital ruler in millimeters from the computed-tomography point to the ultrasound point or external-palpation point. We defined

success as the proportion of accurate attempts within a 5-mm distance from the computed-tomography point to the ultrasound point or external-palpation point. The percentage of accurate attempts, defined as a distance of 5 mm or less, was 10-fold greater in the ultrasound than external-palpation group (81% vs. 8%; 95% CI, 63.6 to 81.3%;  $P < 0.0001$ ).





**Fig. 2.** The distribution of the identified locations in both groups based on vertical and horizontal 5-mm distance from the computer-tomography scan-identified midpoint as the reference.

**Table 2.** Assessment of the Cricothyroid Membrane between Ultrasound and External-palpation Groups

Assessment	Palpation (N = 109)	Ultrasound (N = 114)	Difference (95% CI)	P value
x-Axis, mean $\pm$ SD	1.3 (11.1)	0.8 (2.6)	0.47 (-1.63, 2.57)	0.667
y-Axis, mean $\pm$ SD	10.6 (9.8)	1.4 (3.6)	9.19 (7.26, 11.12)	< 0.0001
Distance from the target, mean $\pm$ SD	16.6 (7.5)	3.4 (3.3)	13.18 (11.67, 14.70)	< 0.0001
Distance from the target $\leq$ 5mm (%)	9 (8%)	92 (81%)	72.4% (63.6%, 81.3%)	< 0.0001

The mean  $\pm$  SD distance measured from the external palpation to the computed-tomography point was five-fold greater than the ultrasound to computed-tomography point ( $16.6 \pm 7.5$  vs.  $3.4 \pm 3.3$  mm; 95% CI, 11.67 to 14.70;  $P < 0.0001$ ; table 2). Poisson regression analysis demonstrated that the risk ratio of inaccurate localization of the cricothyroid membrane was 9.14-fold greater with the external palpation than with the ultrasonography ( $P < 0.0001$ ; table 3). Because both ultrasound and external-palpation techniques are minimally invasive, we did not observe any adverse events in our trial.

## Discussion

The primary outcome of this clinical trial was the accuracy in identification of the cricothyroid membrane, which was measured by a digital ruler in millimeters from the computed-tomography point to the ultrasound point or external-palpation point. We defined success as the proportion

of accurate attempts within a 5-mm distance from the computed-tomography point to the ultrasound point or external-palpation point.

In this trial, ultrasonography was significantly more accurate than external palpation in localizing the cricothyroid membrane of patients with poorly defined neck landmarks. Furthermore, ultrasonography was highly accurate in localizing the cricothyroid membrane as identified with computed-tomography scan, the accepted standard.

An important finding of our study is the high accuracy of ultrasound (81% vs. 8%; 95% CI, 63.6 to 81.3%;  $P < 0.0001$ ; table 3). This is consistent with previous studies looking at ultrasound accuracy with regard to the cricothyroid membrane. Kristensen *et al.*<sup>14</sup> showed an 83% success rate of ultrasound-guided identification of the cricothyroid membrane in morbidly obese females with poorly palpable neck landmarks. Other studies demonstrated a

**Table 3.** Poisson Regression Model with Successful Identification

Effect	Reference	Risk Ratio	95% CI for Risk Ratio		P value
Ultrasound	Palpation	9.14	4.88	17.13	< 0.0001
Body mass index		1.00	0.98	1.03	0.795
Neck circumference		0.98	0.96	1.00	0.062
Thyromental distance		1.02	0.95	1.10	0.624
Sternomental distance		0.94	0.88	1.02	0.139
Ability to extend neck		0.85	0.62	1.17	0.323
Previous surgery		0.90	0.71	1.15	0.413
History of difficult intubation		0.65	0.39	1.06	0.084
Manual identification					
Difficult	Moderate	1.10	0.85	1.43	0.474
Impossible	Moderate	0.51	0.20	1.28	0.150

Successful identification is defined as within 5 mm of the computer-tomography scan-identified spot.

100% identification of the cricothyroid membrane with ultrasonography in obese nonpregnant<sup>8</sup> and obese pregnant subjects.<sup>4</sup> Although ultrasonography can accurately localize the cricothyroid membrane, there is a paucity of evidence to assess its accuracy against computed-tomography scan as the accepted standard. Furthermore, we observed that the mean  $\pm$  SD distance measured from the external-palpation point to the computed-tomography point was five-fold greater than from the ultrasound point to the computed-tomography point ( $16.6 \pm 7.5$  vs.  $3.4 \pm 3.3$  mm; 95% CI, 11.67 to 14.70;  $P < 0.0001$ ; table 2; fig. 2). These findings demonstrate that in subjects with neck pathology and poorly defined neck landmarks, ultrasonography is highly accurate in localizing the cricothyroid membrane and is comparable to computed-tomography scan as the accepted standard.

Accurate localization was defined as within less than 5 mm of the midpoint of the cricothyroid membrane as identified by computed-tomography scan. This value was based on the known dimensions of the cricothyroid membrane in human cadavers with a mean width of 8.2 mm with an upper limit of 11.0 mm and a mean height of 10.4 mm with an upper limit of 13.0 mm.<sup>12</sup> Although the 5-mm limit is arbitrary, the value is based on empirical data and is clinically relevant because a puncture within this limit is likely to occur at the recommended site of placement of cricothyrotomy devices to avoid injuries to the vocal cords,<sup>12</sup> whereas a puncture outside this limit may result in cricothyrotomy failure and/or unnecessary complications.

In contrast to ultrasonography, only 8% (9 of 109) of the points made by external palpation were accurate (table 2), with the majority of points located outside the upper limit of both the width and height of the cricothyroid membrane.<sup>12</sup> Moreover, the calculated mean  $\pm$  SD distance of the points by external palpation was  $16.6 \pm 7.5$  mm (table 2), which is beyond the upper dimensions of the cricothyroid membrane.<sup>12</sup>

Although other studies have demonstrated an accuracy rate of 30 to 71% in patients without neck pathology,<sup>4,6,8,15</sup> we observed a low accurate rate of only 8% in our population with neck pathology. Accurate identification of the

cricothyroid membrane using external palpation is often more difficult than anticipated, even under elective conditions.<sup>7,8,11</sup> A study by Lamb *et al.*<sup>11</sup> showed that anesthesiologist staff and trainees had greater success rates in accurate cricothyroid membrane localization using external palpation in nonobese males (33 of 46, 71.7%) than females (11 of 45, 24.4%) without poor neck landmarks. It is likely that the prominent thyroid cartilage in males allows for the cricothyroid membrane to be more accurately localized.<sup>11</sup> In another study, Aslani *et al.*<sup>8</sup> reported success rates of 24.4% and 29.3% using external palpation in nonobese women with the neck placed in the neutral and extended positions, respectively. Furthermore, trauma surgeons with experience in surgical airways had a similar success rate of 26% in female volunteers.<sup>7,16</sup> In contrast to external palpation, these studies further demonstrated that ultrasound was successful in accurately localizing the cricothyroid membrane in all the subjects. These findings are concerning and might have important clinical implications in a life-threatening “cannot intubate, cannot oxygenate” situation, in which mislocalization of the cricothyroid membrane by external palpation in patients with neck pathology might lead to failed cricothyrotomies.

Our results may support the high failure rate of operating room emergency needle cricothyrotomies reported in the Fourth National Audit Project study, the largest clinical study on major airway complications of more than 2 million patients during general anesthesia.<sup>17</sup> Although many factors could cause the high failure rate, misidentification of the cricothyroid membrane using external palpation during an emergency cricothyrotomy might be a contributing factor, because 39% of patients in the aforementioned study have neck pathology that may make the cricothyroid membrane more difficult to localize.<sup>17</sup>

The use of ultrasonography in airway management is steadily increasing. Several difficult airway guidelines advocate the use of preprocedure ultrasound to identify the neck landmarks and the cricothyroid membrane before airway management in patients with difficult airways.<sup>4,18</sup> The American Society of Anesthesiologists Difficult Airway Algorithm categorizes a group of patients with “difficult

surgical access.”<sup>18</sup> Although the specifics of this patient population are not stated, our findings suggest that neck pathology creates a challenge for identifying neck landmarks by external palpation. Premarking the cricothyroid membrane with ultrasonography in patients with neck pathology could theoretically improve success of a cricothyrotomy and reduce complications when performing this high-stakes procedure.

In a study on human cadavers with poorly defined neck landmarks, Siddiqui *et al.*<sup>2</sup> showed a significantly greater success rate of cricothyrotomy and a three-fold reduction in complications with ultrasound identification compared to external palpation of the cricothyroid membrane. Dinsmore *et al.*<sup>15</sup> demonstrated a significant increase in success rate and a significant decrease in procedure time of cannula tracheotomy using ultrasound-guided compared to non-ultrasound-guided cannula placement in a model with simulated unidentifiable anterior neck anatomy. Furthermore, ultrasound guidance has been shown to facilitate successful puncture between tracheal rings in eight of nine cadavers at the first attempt.<sup>19</sup>

In addition, a limited number of reported clinical cases appear to support the potential value of preprocedural ultrasound. Muhammad *et al.*<sup>20</sup> described four case reports in which ultrasound helped to identify aberrant anatomical variations to safely perform percutaneous tracheostomy or elective open tracheostomy. In a morbidly obese patient with impalpable neck landmarks, tracheostomy was successfully performed under ultrasound guidance.<sup>21</sup> Another case report described that preprocedural ultrasound identification of the cricothyroid membrane resulted in prompt and successful emergency cricothyroidotomy without complications. This was after multiple failed attempts at awake fiberoptic intubation in a patient with airway swelling and impossible neck landmarks secondary to von Recklinghausen disease.<sup>22</sup> Ultrasonography has been proven to increase success, decrease complications, and enhance patient safety when performing invasive procedures.<sup>23</sup> Our study, together with previous reports, suggest the potential role of ultrasound in improving the success and minimizing the complications of performing a cricothyrotomy when the cricothyroid membrane is premarked, particularly in patients with neck pathologies in which the neck landmarks and cricothyroid membrane are poorly defined.

In a study performed on obese laboring patients, increased neck circumference was an independent risk factor for poor accuracy in localizing the cricothyroid membrane using external palpation,<sup>4</sup> which was inconsistent with the finding of our study. Underlying tissue responsible for increasing neck circumference does not appear to affect ultrasound localization of the cricothyroid membrane, and several studies reported accurate cricothyroid membrane localization with ultrasound of obese and morbidly obese volunteers with increased neck circumference.<sup>4,6,8</sup>

Our study has several limitations. The cricothyroid membrane was assessed on patients in the neutral neck position. Location of the cricothyroid membrane is variable

depending on the position of the neck,<sup>8</sup> and a less than ideal neutral neck position could have affected the accuracy of the cricothyroid membrane. However, a donut-shaped pillow was used to minimize head movement and maintained the neck in the neutral position during computed-tomography scan. The cricothyroid membrane was identified by two study investigators (D.D., S.B.) using ultrasonography and external palpation. The homogeneity of the assessors could bias the outcomes through learning with repeated assessments. However, this did not appear to be the case because the proportion of accurate points by external palpation was only 8% (9 of 109). Although the two assessors were anesthesia fellows, evidence suggests that clinical experience did not appear to affect the performance in localizing the cricothyroid membrane using external palpation. Such evidence includes a number of studies in which staff anesthesiologists, emergency physicians, surgeons, and anesthesia residents performed equally poorly in localizing the cricothyroid membrane.<sup>5-7</sup>

In conclusion, for patients with neck pathology and poorly defined neck anatomy, ultrasound was significantly more accurate than external palpation in localizing the cricothyroid membrane. In addition, ultrasonography was highly accurate in localizing the cricothyroid membrane identified with computed-tomography scan as the accepted standard. These results support the use of ultrasonography over the conventional approach of external palpation for the prelocalization of the cricothyroid membrane in patients with neck pathology before airway management in anticipation of difficult airways. Our results are widely generalizable to the population who might have history of difficult intubation, surgery on the neck, neck mass, and neck irradiation.

## Acknowledgments

The authors acknowledge the efforts of Sahar Farzi, M.D., Shaqayeq Marashi, M.D., and Devdatta Desi, M.D. (all from the Department of Anesthesia and Pain Management, Mount Sinai Hospital, University of Toronto, Toronto, Canada) for their assistance as research associates to conduct this study. We also acknowledge the Department of Anesthesia and Pain Management of Mount Sinai Hospital for providing equipment support.

## Research Support

Supported by the Department of Anesthesia and Pain Management, Mount Sinai Hospital and Sinai Health System, Toronto, Canada.

## Competing Interests

The authors declare no competing interests.

## Reproducible Science

Full protocol available at: naveed.siddiqui@uhn.ca. Raw data available at: naveed.siddiqui@uhn.ca.

## Correspondence

Address correspondence to Dr. Siddiqui: University of Toronto, 600 University Avenue, Room 19-104, Toronto, Ontario M5G 1X5, Canada. naveed.siddiqui@uhn.ca. This article may be accessed for personal use at no charge through the Journal Web site, [www.anesthesiology.org](http://www.anesthesiology.org).

## References

- Kristensen MS, Teoh WH, Graumann O, Laursen CB: Ultrasonography for clinical decision-making and intervention in airway management: From the mouth to the lungs and pleurae. *Insights Imaging* 2014; 5:253–79
- Siddiqui N, Arzola C, Friedman Z, Guerina L, You-Ten KE: Ultrasound improves cricothyrotomy success in cadavers with poorly defined neck anatomy: A randomized control trial. *ANESTHESIOLOGY* 2015; 123:1033–41
- Kristensen MS: Ultrasonography in the management of the airway. *Acta Anaesthesiol Scand* 2011; 55:1155–73
- You-Ten KE, Desai D, Postonogova T, Siddiqui N: Accuracy of conventional digital palpation and ultrasound of the cricothyroid membrane in obese women in labour. *Anaesthesia* 2015; 70:1230–4
- Elliott DS, Baker PA, Scott MR, Birch CW, Thompson JM: Accuracy of surface landmark identification for cannula cricothyroidotomy. *Anaesthesia* 2010; 65:889–94
- Nicholls SE, Sweeney TW, Ferre RM, Strout TD: Bedside sonography by emergency physicians for the rapid identification of landmarks relevant to cricothyrotomy. *Am J Emerg Med* 2008; 26:852–6
- Hiller KN, Karni RJ, Cai C, Holcomb JB, Hagberg CA: Comparing success rates of anesthesia providers *versus* trauma surgeons in their use of palpation to identify the cricothyroid membrane in female subjects: A prospective observational study. *Can J Anaesth* 2016; 63:807–17
- Aslani A, Ng SC, Hurley M, McCarthy KF, McNicholas M, McCaul CL: Accuracy of identification of the cricothyroid membrane in female subjects using palpation: An observational study. *Anesth Analg* 2012; 114:987–92
- Oliveira KF, Arzola C, Ye XY, Clivatti J, Siddiqui N, You-Ten KE: Determining the amount of training needed for competency of anesthesia trainees in ultrasonographic identification of the cricothyroid membrane. *BMC Anesthesiol* 2017; 17:74
- Kristensen MS, Teoh WH, Rudolph SS, Hessfeldt R, Børglum J, Tvede MF: A randomised cross-over comparison of the transverse and longitudinal techniques for ultrasound-guided identification of the cricothyroid membrane in morbidly obese subjects. *Anaesthesia* 2016; 71:675–83
- Lamb A, Zhang J, Hung O, Flemming B, Mullen T, Bissell MB, Arseneau I: Accuracy of identifying the cricothyroid membrane by anesthesia trainees and staff in a Canadian institution. *Can J Anaesth* 2015; 62:495–503
- Dover K, Howdieshell TR, Colborn GL: The dimensions and vascular anatomy of the cricothyroid membrane: Relevance to emergent surgical airway access. *Clin Anat* 1996; 9:291–5
- Boon JM, Abrahams PH, Meiring JH, Welch T: Cricothyroidotomy: A clinical anatomy review. *Clin Anat* 2004; 17:478–86
- Kristensen MS, Teoh WH, Rudolph SS, Tvede MF, Hessfeldt R, Børglum J, Lohse T, Hansen LN: Structured approach to ultrasound-guided identification of the cricothyroid membrane: A randomized comparison with the palpation method in the morbidly obese. *Br J Anaesth* 2015; 114:1003–4
- Dinsmore J, Heard AM, Green RJ: The use of ultrasound to guide time-critical cannula tracheotomy when anterior neck airway anatomy is unidentifiable. *Eur J Anaesthesiol* 2011; 28:506–10
- Law JA: Deficiencies in locating the cricothyroid membrane by palpation: We can't and the surgeons can't, so what now for the emergency surgical airway? *Can J Anaesth* 2016; 63:791–6
- Cook TM, Woodall N, Frerk C; Fourth National Audit Project: Major complications of airway management in the UK: Results of the Fourth National Audit Project of the Royal College of Anaesthetists and the Difficult Airway Society: Part 1. *Anaesthesia*. *Br J Anaesth* 2011; 106:617–31
- Apfelbaum JL, Hagberg CA, Caplan RA, Blitt CD, Connis RT, Nickinovich DG, Hagberg CA, Caplan RA, Benumof JL, Berry FA, Blitt CD, Bode RH, Cheney FW, Connis RT, Guidry OF, Nickinovich DG, Ovassapian A; American Society of Anesthesiologists Task Force on Management of the Difficult Airway: Practice guidelines for management of the difficult airway: An updated report by the American Society of Anesthesiologists Task Force on Management of the Difficult Airway. *ANESTHESIOLOGY* 2013; 118:251–70
- Kleine-Bruegeney M, Greif R, Ross S, Eichenberger U, Moriggl B, Arnold A, Luyet C: Ultrasound-guided percutaneous tracheal puncture: A computer-tomographic controlled study in cadavers. *Br J Anaesth* 2011; 106:738–42
- Muhammad JK, Major E, Wood A, Patton DW: Percutaneous dilatational tracheostomy: Haemorrhagic complications and the vascular anatomy of the anterior neck. A review based on 497 cases. *Int J Oral Maxillofac Surg* 2000; 29:217–22
- Sustić A, Zupan Z, Antončić I: Ultrasound-guided percutaneous dilatational tracheostomy with laryngeal mask airway control in a morbidly obese patient. *J Clin Anesth* 2004; 16:121–3
- Owada G, Inagawa G, Nakamura K, Kariya T, Goto T: [Usefulness of ultrasound pre-scanning for cricothyroid membrane puncture in a patient with rupture of a pseudoaneurysm]. *Masui* 2014; 63:77–80
- Dinh VA, Farshidpanah S, Lu S, Stokes P, Chrissian A, Shah H, Giri P, Hecht D, Nguyen HB: Real-time sonographically guided percutaneous dilatational tracheostomy using a long-axis approach compared to the landmark technique. *J Ultrasound Med* 2014; 33:1407–15